

Diagnostic Accuracy of Right Ventricular Dysfunction Markers in Normotensive Emergency Department Patients With Acute Pulmonary Embolism



Anthony J. Weekes, MD*; Gregory Thacker, MD; Daniel Troha, MD; Angela K. Johnson, MD; Jordan Chanler-Berat, MD; H. James Norton, PhD; Michael Runyon, MD

*Corresponding Author. E-mail: anthony.weekes1@gmail.com.

Study objective: We determine the diagnostic accuracy of goal-directed echocardiography, cardiac biomarkers, and computed tomography (CT) in early identification of severe right ventricular dysfunction in normotensive emergency department patients with pulmonary embolism compared with comprehensive echocardiography.

Methods: This was a prospective observational study of consecutive normotensive patients with confirmed pulmonary embolism. Investigators, blinded to clot burden and biomarkers, performed qualitative goal-directed echocardiography for right ventricular dysfunction: right ventricular enlargement (diameter greater than or equal to that of the left ventricle), severe right ventricular systolic dysfunction, and septal bowing. Brain natriuretic peptide and troponin cutoffs of greater than or equal to 90 pg/mL and greater than or equal to 0.07 ng/mL and CT right ventricular:left ventricular diameter ratio greater than or equal to 1.0 were also compared with comprehensive echocardiography.

Results: One hundred sixteen normotensive pulmonary embolism patients (111 confirmed by CT, 5 by ventilation-perfusion scan) were enrolled. Twenty-six of 116 patients (22%) had right ventricular dysfunction on comprehensive echocardiography. Goal-directed echocardiography had a sensitivity of 100% (95% confidence interval [CI] 87% to 100%), specificity of 99% (95% CI 94% to 100%), positive likelihood ratio (+LR) of 90.0 (95% CI 16.3 to 499.8), and negative likelihood ratio (-LR) of 0 (95% CI 0 to 0.13). Brain natriuretic peptide had a sensitivity of 88% (95% CI 70% to 98%), specificity of 68% (95% CI 57% to 78%), +LR of 2.8 (95% CI 2.0 to 3.9), and -LR of 0.17 (95% CI 0.06 to 0.43). Troponin had a sensitivity of 62% (95% CI 41% to 80%), specificity of 93% (95% CI 86% to 98%), +LR of 9.2 (95% CI 4.1 to 20.9), and -LR of 0.41 (95% CI 0.24 to 0.62). CT had a sensitivity of 91% (95% CI 72% to 99%), specificity of 79% (95% CI 69% to 87%), +LR of 4.3 (95% CI 2.8 to 6.7), and -LR of 0.11 (95% CI 0.03 to 0.34).

Conclusion: Goal-directed echocardiography was highly accurate for early severe right ventricular dysfunction identification and pulmonary embolism risk-stratification. Brain natriuretic peptide was sensitive but less specific, whereas troponin had lower sensitivity but higher specificity. CT had good sensitivity and moderate specificity. [Ann Emerg Med. 2016;68:277-291.]

Please see page 278 for the Editor's Capsule Summary of this article.

A **feedback** survey is available with each research article published on the Web at www.annemergmed.com.

A **podcast** for this article is available at www.annemergmed.com.

0196-0644/\$-see front matter

Copyright © 2016 by the American College of Emergency Physicians.

<http://dx.doi.org/10.1016/j.annemergmed.2016.01.027>

INTRODUCTION

Background

Pulmonary embolism is an important and challenging clinical condition that may present insidiously or significantly. It can increase pulmonary artery pressures and obstruct outflow from the right ventricle, causing its dilatation. Further deterioration may result in right ventricular ischemic injury and compromised left ventricular function. Only 5% of pulmonary embolisms

present with overt signs and symptoms of shock and are considered massive. These patients are at high risk for morbidity and mortality.¹ The majority of pulmonary embolism patients present without hypotension and shock symptoms.²

Patients with normotensive pulmonary embolism have many permutations of clinical characteristics and comorbid conditions. Right ventricular dysfunction is an important prognostic tool for these patients. In the subsequent

Editor's Capsule Summary*What is already known on this topic*

Assessments of right ventricular function in pulmonary embolism can inform clinical decisions, including the need for thrombolytics and the necessity for inpatient hospitalization. The optimal means of assessing right ventricular dysfunction is unknown.

What question this study addressed

This study examined the test characteristics of goal-directed echocardiography (performed by 5 physicians with extra training), brain natriuretic peptide, troponin, and computed tomography in identifying right ventricular function in patients with pulmonary embolism.

What this study adds to our knowledge

Goal-directed echocardiography by these physicians exhibited high sensitivity and specificity, and was superior to other tests in detecting or excluding early severe right ventricular dysfunction.

How this is relevant to clinical practice

If these findings can be shown to be valid for the typical emergency physician, goal-directed echocardiography will enable emergency physicians to improve management of patients with pulmonary embolism.

discussions, we will be referring to severe right ventricular dysfunction detection by goal-directed echocardiography.

Right ventricular dysfunction is definitively identified with transthoracic echocardiography but can also be assessed with cardiac biomarkers. Elevated serum cardiac brain natriuretic peptide and troponin levels can serve as surrogate markers of right ventricular dilatation and myocardial ischemic injury, respectively.^{2,3} Patients without overt signs and symptoms of shock but with latent right ventricular dysfunction can later develop hypotension, cardiorespiratory deterioration, or death despite prompt initiation of anticoagulation at diagnosis. Survivors to hospital discharge may have persistent right heart strain and functional limitations if treated only with standard anticoagulation therapy.⁴⁻⁷ Not all patients with pulmonary embolism, however, require admission to the hospital. Recent studies and protocols have shown that patients with low-risk pulmonary embolism can be safely sent home (as per Pulmonary Embolism Severity Index and Hestia criteria). In addition, patients without signs or

markers for right ventricular dysfunction can be considered for abbreviated observational monitoring and treatment or outpatient treatment.⁸⁻¹¹

Importance

Risk stratification of normotensive patients with pulmonary embolism can be challenging. The presence of right ventricular dysfunction in pulmonary embolism is a predictor of short-term hemodynamic collapse and long-term morbidity. Ideally, the identification of right ventricular dysfunction can guide clinical management and disposition decisions. Patients with right ventricular dysfunction signs may be considered for interventions beyond anticoagulation, including systemic or catheter-based thrombolysis. Additionally, they may require more intensive clinical monitoring. Patients without right ventricular dysfunction and other low-risk clinical signs may be candidates for shorter hospital stays or may be even discharged from the emergency department (ED), receiving oral anticoagulants.

The right ventricle has a complex shape and function and is best assessed by cardiac magnetic resonance imaging, 3-dimensional echocardiography, and transesophageal echocardiography, but none of these is a feasible first-line option in the critical care or ED setting. Comprehensive echocardiography is the routinely used standard for right ventricular dysfunction assessment. It is usually performed by a certified sonographer and interpreted by a cardiologist but is often not immediately available on evenings, nights, or weekends. It involves multiple technologies, including 2-dimensional, M-mode, and other Doppler modalities (color, pulsed-wave, continuous-wave, and tissue Doppler); however, the primary, fundamental, and time-sensitive clinical goal of echocardiography in the setting of pulmonary embolism is the detection of right ventricular enlargement and right ventricular systolic dysfunction.

The optimal pulmonary embolism risk-stratification tool is both immediately available and accurate. Possible strategies meeting both of these criteria include right ventricular assessment with computed tomography (CT), serum cardiac biomarkers, and goal-directed echocardiography performed by the emergency physician. The assessment of right ventricular dilatation with focused cardiac ultrasonography is supported in the core curriculum and the consensus statement of the American College of Emergency Physicians and American Society of Echocardiography.¹²⁻¹⁴ Although many studies support the feasibility and diagnostic accuracy of qualitative assessment of left ventricular function by cardiologists and emergency physicians, the literature is limited on the diagnostic accuracy of emergency physician echocardiography assessment of the right ventricular. Although CT is

considered the reference standard for the diagnosis of pulmonary embolism (filling defects in the contrast enhanced pulmonary arteries), measurements of the dimensions of the heart chambers can also provide important information on right ventricular strain and, indirectly, prognostic stratification.¹⁵

Goals of This Investigation

The primary goal was to determine test characteristics of goal-directed echocardiography for right ventricular dysfunction assessment performed and interpreted by emergency physicians. Our secondary goal was to determine test characteristics of serum cardiac biomarkers and CT for right ventricular dysfunction detection. We used predefined right ventricular dysfunction criteria for each index test. Our hypothesis was that early use of point-of-care right ventricular dysfunction testing would accurately identify right ventricular dysfunction in patients with acute normotensive pulmonary embolism. We evaluated our findings with comprehensive echocardiography as the reference standard.

MATERIALS AND METHODS

Study Design and Setting

We performed a prospective study of diagnostic accuracy on a consecutive sample of normotensive ED patients who received a diagnosis of acute pulmonary embolism confirmed by either computed tomography angiography or ventilation-perfusion scan. The study was conducted in the ED at Carolinas Medical Center in Charlotte, NC, from July 2014 to July 2015. The setting was an academic urban hospital with 121,000 visits per year. The Carolina HealthCare System Investigational Review Board approved this clinical research study. Written informed consent was required.

Goal-directed echocardiography was considered a minimal risk to the patient. It is a well-established and important application used for patients in our ED. Serum brain natriuretic peptide and troponin level testing was part of the standard risk stratification of patients with a high likelihood of, or confirmation of, pulmonary embolism and was recommended by the American College of Emergency Physicians (ACEP) clinical policy guidelines on clinical management of pulmonary embolism and by the American Heart Association (AHA).^{2,5}

The study was conducted at an ED staffed by emergency medicine resident physicians, advanced care providers, and board-certified emergency physicians with a well-established emergency ultrasonographic program and an emergency ultrasonographic fellowship. One of 5 trained emergency physician investigators performed goal-directed echocardiography before comprehensive echocardiography. The principal investigator of this study (AJW) was the director of the emergency ultrasonographic fellowship

program and was certified as a registered diagnostic cardiac sonographer. Of the other 4 physician investigators, 1 was an emergency ultrasonographic fellow and 3 were emergency medicine residents, and all had received training in goal-directed echocardiography and undergone more intensive training before the start of the research study. Training included a 2-hour lecture focusing on the principles of goal-directed cardiac echocardiography and 6 hours of hands-on experience supervised by the principal investigator. All physician investigators had completed, at a minimum, a 1-month ultrasonographic rotation during residency training and had performed more than 50 cardiac ultrasonographic procedures.

Selection of Participants

Study investigators monitored the ED electronic tracking board (FirstNet; Cerner Corporation, Kansas City, MO) for patients. Additionally, all ED providers were notified of the study and asked to call a central paging operator on diagnosis of image-confirmed pulmonary embolism. The operator notified the study investigators by simultaneous group text messaging (without patient identifiers) and through the secure hospital e-mail with patient name and identifiers.

Patients were consecutively enrolled if they met the following inclusion criteria: aged 18 years or older and with confirmed acute pulmonary embolism according to the results of computed tomography angiography or high-probability ventilation-perfusion scan. Patients were excluded if massive pulmonary embolism criteria were met, if they were unable to tolerate the echocardiogram, or if the ultrasonographic images were of inadequate quality. We used the American Heart Association definition of massive pulmonary embolism: acute pulmonary embolism with sustained hypotension (systolic blood pressure <90 mm Hg for at least 15 minutes or requiring inotropic support, and not caused by anything other than pulmonary embolism, such as arrhythmia, hypovolemia, sepsis, or left ventricular dysfunction), pulselessness, or persistent profound bradycardia (pulse rate <40 beats/min with signs or symptoms of shock).⁵ As part of the inclusion criteria, comprehensive echocardiography had to be performed within 24 hours of pulmonary embolism diagnosis, but patients would be excluded if aggressive pulmonary embolism intervention (systematic or catheter-directed thrombolysis or surgical embolectomy) occurred between goal-directed echocardiography and comprehensive echocardiography.

Goal-directed echocardiography was performed and interpreted by the emergency physician. These results were compared with that for comprehensive echocardiogram (comprehensive echocardiography) performed by a

registered diagnostic cardiac sonographer and interpreted by a board-certified cardiologist. The physician-investigator performing the goal-directed echocardiography was blinded to results of CT and serum markers.

Data Collection and Processing

If patients who received a diagnosis of acute pulmonary embolism met inclusion criteria, they were enrolled in the study. Patient demographics, initial vital signs, and comorbidities were recorded.

Goal-directed echocardiography focused on the presence or absence of the following characteristics: visual estimate of severe right ventricular enlargement (diameter greater than or equal to the left ventricular diameter), severe right ventricular hypokinesis, and interventricular septum flattening or bowing into the left ventricle. Additionally, the sonographer noted the presence or absence of poor left ventricular systolic function according to visual estimation. The range of times between pulmonary embolism diagnosis and goal-directed echocardiography completion was 1 hour before to 2 hours after pulmonary embolism confirmation. A few outliers were between 4 and 6 hours later, but none occurred after comprehensive echocardiography.

Meta-analyses of the prognostic value of echocardiography for right ventricular function in pulmonary embolism have shown that there are many different parameters and permutations used to assess and define right ventricular dysfunction. The common right ventricular dysfunction definition criteria used are right ventricular dilatation, right ventricular systolic dysfunction, or both. The individual studies selected in meta-analyses used a variety of cutoffs for right ventricular dilatation, such as right ventricular:left ventricular ratio (range 0.9 to -1.4) or right ventricular basal diameter greater than 30 mm and different permutations of the variables right ventricular systolic function, Doppler measurements, and septal and inferior vena cava features. In accordance with our review of the literature, we decided that right ventricular:left ventricular ratio greater than or equal to 1.0, longitudinal shortening of the right ventricle, and septal deviation were the most established and feasible criteria for emergency physician-performed goal-directed echocardiography.¹⁶⁻¹⁸

The criteria we used for the qualitative assessment of the right ventricle are shown in Figure 1. The presence of severe right ventricular enlargement was determined by the presence of blunting of the right ventricular apex and a comparison of the diastolic diameter at the base of both ventricles. The complex anatomy and function of the right ventricle can create limitations to right ventricular assessments on each echocardiographic window. All goal-directed echocardiographic windows were factored in to refute or support the presence or

Severe Right Ventricular Enlargement

Absent: Narrow and sharp right ventricular apex, basal diameter of right ventricle (normal 2.0–2.8 cm), and right ventricular:left ventricular ratio (normal 0.4–0.6)

Present: Blunt right ventricular apex, basal right ventricular diameter >3.8 cm, and right ventricle equal or greater than left ventricle

Severe Right Ventricular Systolic Dysfunction

Absent: Inward movement of right ventricular free wall (normal right ventricular fractional change 32%–60%) and axial right ventricular annulus movement (tricuspid annular planar systolic excursion 1.5–2.0 cm)

Present: Minimal to absent movement of right ventricular free wall annulus (tricuspid annular planar systolic excursion <1.0 cm) and diminished inward movement of right ventricular free wall (fractional change $<18\%$), in addition to the following:

Ventricular Septum Contour

Normal: Bowed toward the right ventricle

Abnormal: Flattened or bowed toward the left ventricle

Figure 1. Qualitative goal-directed echocardiography assessment of right ventricular function.^{19,20}

absence of right ventricular enlargement. We used the apical and subcostal windows to determine the presence or absence of right ventricular apex blunting.

Visual estimations of severe right ventricular systolic function factored in the movement of the tricuspid annulus along the long axis of the right ventricle (termed *tricuspid annular planar systolic excursion*) and the inward movement of the free wall of the right ventricle during systole. The movement of the tricuspid annulus was visually estimated, and no actual tricuspid annular planar systolic excursion measurement was necessary for completion of goal-directed echocardiography.

Study investigators recorded 3-second, digital, 2-dimensional video clips of parasternal long- and short-axis views (mitral valve level) and subcostal and apical 4-chamber views with a Philips Sparq ultrasonographic machine and its S 1-5 MHz phased-array transducer (Philips Ultrasound, Andover, MA).

The study investigators used the presence of at least one of the abovementioned features in two or more of the abovementioned goal-directed echocardiographic views. If one or more of the features was present in at least

two of the ultrasonographic views, the goal-directed echocardiography result was considered positive for right ventricular dysfunction.

We considered the tricuspid annular planar systolic excursion to be as important as, if not more important than, inward right ventricular motion in the evaluation of right ventricular systolic assessment. Tricuspid annulus movement could be qualitatively compared with mitral annulus movement as a reference.²¹ Typically, normal tricuspid annular planar systolic excursion is 60% more than the normal mitral annulus movement along the long axis of the heart. Tricuspid annular planar systolic excursion has been identified as an important echocardiographic and clinical hazard risk in patients with initially normotensive pulmonary embolism.²²

Cardiac biomarker testing was performed with the i-STAT cTnI test cartridge (Abbott Point of Care, Abbott Park, IL) and i-STAT brain natriuretic peptide test cartridge (Abbott Point of Care). According to guidelines published by the American Heart Association in 2011, brain natriuretic peptide values greater than 90 pg/mL were considered elevated. Troponin I values greater than or equal to 0.07 ng/mL were considered elevated according to our institution's reference range.⁵

The 2 components for point-of-care screening for right ventricular dysfunction were goal-directed echocardiography and cardiac serum markers. The following criteria were used to define point-of-care testing results as positive for right ventricular dysfunction and to define a right ventricular dysfunction severity scale based on the unique pathophysiology of right ventricular dysfunction in acute pulmonary embolism.^{23,24} For goal-directed echocardiography and a right ventricular dysfunction severity scale of 0 to 3, the following were used: 0=absence of severe right ventricular enlargement (see definition); 1=presence of severe right ventricular enlargement (necessary condition); 2=presence of severe right ventricular enlargement and severe right ventricular hypokinesis (see definition), or septal flattening or bowing, or right ventricular hypokinesis; and 3=presence of severe right ventricular enlargement and severe right ventricular hypokinesis (see definition) and septal flattening or bowing. For the cardiac biomarkers right ventricular dysfunction scale of 0 to 2, 0=absence of elevated serum marker (see definition), 1=presence of brain natriuretic peptide level elevation or troponin level elevation, and 2=presence of brain natriuretic peptide level elevation and troponin level elevation. A score of zero was considered negative for right ventricular dysfunction for both point-of-care testing components. A score of 1 to 3 by goal-directed echocardiography was considered positive for right ventricular dysfunction. A score of 1 or 2 by cardiac biomarkers was considered positive.

The study investigator who performed goal-directed echocardiography was blinded to cardiac biomarker level results and CT report on right ventricular dysfunction. In the event a study investigator became aware of cardiac biomarker level results or CT interpretation, a different study investigator performed goal-directed echocardiography. The bedside assessment of right ventricular dysfunction with 2-dimensional goal-directed echocardiography was performed and interpreted by study investigators or a delegate and then compared with subsequent comprehensive echocardiography (acquired by a cardiology division sonographer and interpreted by a cardiologist). Each goal-directed echocardiographic test was performed before the comprehensive echocardiography. The goal-directed echocardiography operator was blinded to all comprehensive echocardiography reports. The cardiology division staff members involved in the comprehensive echocardiography (sonographer and cardiologist) were blinded to the earlier goal-directed echocardiography results.

Board-certified body radiologists interpreted the CT scans. The report included information on the presence or absence of central or lobar clot and right ventricular dilatation. Any right ventricular:left ventricular diameter ratio measurement greater than or equal to 1.0 was considered positive for right ventricular dysfunction. Board-certified nuclear medicine radiologists interpreted the ventilation-perfusion scans, and a "high-probability" result in a symptomatic patient was considered diagnostic of pulmonary embolism. The CT measurement of right ventricular dysfunction was not available for patients whose pulmonary embolisms were diagnosed by ventilation-perfusion scan.

The panel of point-of-care tests results was compared with comprehensive echocardiography specifically requested for pulmonary embolism evaluation. Comprehensive echocardiography report comments of severe right ventricular enlargement, severe systolic dysfunction, or septal deviation were considered positive for each pertinent right ventricular dysfunction criterion. Additional findings such as left ventricular systolic function septal wall flattening or bowing, right ventricular systolic pressure, and the presence of patent foramen ovale and atrial septal defects were also recorded.

A few months into the research study, two emergency medicine residents reviewed a subset of previously recorded goal-directed echocardiography videos and interpreted the presence or absence of right ventricular enlargement or more right ventricular dysfunction features. The reviewers were blinded to patient identifiers, sequence of images, and the clinical course and management of the patient. They were also blinded to the clinical context of the patients. The reviewers received training in right ventricular dysfunction

assessment guidelines with goal-directed echocardiography after completing the 30-minute right ventricular dysfunction in goal-directed echocardiography training tutorial provided by the principal investigator.

Outcome Measures

The primary outcome was the test characteristics of goal-directed echocardiography for the determination of right ventricular dysfunction with comprehensive echocardiography as the criterion standard.

Secondary outcomes included (1) test characteristics of serum brain natriuretic peptide for determination of right ventricular dysfunction, (2) test characteristics of troponin I for determination of right ventricular dysfunction; (3) test characteristics of a right ventricular:left ventricular ratio greater than or equal to 1.0 on CT imaging for determination of right ventricular dysfunction; (4) test characteristics of proximal clot location for determination of right ventricular dysfunction; and (5) interobserver agreement for the presence of right ventricular dysfunction on goal-directed echocardiography video clips.

Primary Data Analysis

A sample size estimate using the method described by Buderer²⁵ was calculated. Assuming that goal-directed echocardiography has a sensitivity of 90% and specificity of 85% for detecting right ventricular dysfunction in our patient cohort, a confidence interval (CI) of 10%, and a 30% prevalence of right ventricular dysfunction in a patient cohort with confirmed pulmonary embolism, we calculated a sample size of 116 patients. A meta-analysis by Coutance et al¹⁷ showed a right ventricular dysfunction prevalence ranging between 50% and 72% in patients with pulmonary embolism without hemodynamic compromise. We chose a more conservative estimate of the right ventricular dysfunction prevalence according to the investigators' collective clinical experience. Study data were collected and managed with Research Electronic Data Capture tools hosted at Carolinas Medical Center (Charlotte, NC). Research Electronic Data Capture is a secure, Web-based application designed to support data capture for research studies, providing an intuitive interface for validated data entry, audit trails for tracking data manipulation and export procedures, automated export procedures for seamless data downloads to common statistical packages, and procedures for importing data from external sources.²⁶

Descriptive statistics, including means and SDs, or counts and percentages, were calculated. Goal-directed echocardiography was compared with comprehensive echocardiography to assess for right ventricular dysfunction (right ventricular enlargement, poor right ventricular systolic

function, and septal deviation). The sensitivity, specificity, positive and negative likelihood ratios, and corresponding 95% CI for right ventricular dysfunction were calculated for each diagnostic test, using comprehensive echocardiography as the criterion standard. Given that the majority of the ultrasonographic scans were completed by a relatively small group of physicians, the test characteristic CIs were adjusted for the resulting cluster correlation.²⁷

Receiver operating characteristic curves were plotted for each diagnostic test, using comprehensive echocardiography as the criterion standard. The areas under the curve were calculated directly by the extended trapezoidal rule, and the corresponding CIs were calculated with Delong's variance estimate.²⁸ Interobserver agreement on goal-directed echocardiography right ventricular dysfunction rating for a subset of patients was reported as the linear weighted Cohen's κ with 95% CIs. $P < .05$ was considered statistically significant. StatsDirect (version 3.0.133; StatsDirect, Cheshire, UK) was used for all analyses.

RESULTS

Characteristics of Study Subjects

Between July 2014 and July 2015, we approached 133 consecutive patients with reported image-confirmed pulmonary embolism. We excluded 4 patients because of current hypotension, 3 because of poor-quality echocardiographic images (could not be interpreted), and 4 because of radiologist clarification that the pulmonary embolism findings were long-term and unchanged. One patient refused consent. We completed goal-directed echocardiography on 122 patients with normotensive pulmonary embolism. Six of these patients (all without right ventricular dysfunction by goal-directed echocardiography) did not receive comprehensive echocardiography. The fellowship director (A.J.W.) performed goal-directed echocardiography on 31 patients (26.7%), a third-year emergency medicine resident (D.T.) performed it on 22 patients (18.9%), an emergency medicine ultrasonographic fellow (J.C.-B.) performed it on 18 patients (15.5%), a second-year emergency medicine resident (G.T.) performed it on 13 patients (11.2%), a second-year emergency medicine resident (A.K.J.) performed it on 19 patients (16.3%), and a group of 10 other emergency physicians (consisting of 8 residents and 2 attending physicians) performed it on 13 patients (11.2%). There was only one instance in which the study investigator became aware of the right ventricular report on CT at enrollment, and a different but blinded study investigator performed and interpreted the goal-directed echocardiography instead.

The reference test, comprehensive echocardiography, was compared with goal-directed echocardiography

in 116 of these patients. All comprehensive echocardiography was performed and interpreted after goal-directed echocardiography. Cardiologists and sonographers were unaware of the results of the goal-directed echocardiography. The study enrollment flow diagram of goal directed echocardiography results compared to comprehensive echocardiography results is shown in Figure 2. The clinical characteristics of the 116 enrolled patients are shown in Table 1. Significant differences were pulse oximetry (patients with right ventricular dysfunction tended to have lower SpO₂) and a history of hypertension (more common in patients with right ventricular dysfunction).

We used predefined cutoff definitions for right ventricular dysfunction. The test characteristics results of goal-directed echocardiography, brain natriuretic peptide level, troponin level, and CT right ventricular:left ventricular ratio for right ventricular dysfunction detection compared with comprehensive echocardiography are shown in Table 2. Proximal thrombus locations (central or lobar arteries) in contrast to more distal thrombi within

segmental arteries were also compared with the presence or absence of right ventricular dysfunction on comprehensive echocardiography (Figure 3).

The goal-directed echocardiography sensitivity and specificity for right ventricular dysfunction were 100% (95% CI 87% to 100%) and 99% (95% CI 94% to 100%), respectively, when the score was greater than or equal to 1. The positive likelihood ratio of goal-directed echocardiography was 90.0 (95% CI 16.3 to 499.8) and the negative likelihood ratio was 0 (95% CI 0 to 0.13). If we assume that all 3 patients with poor-quality echocardiographic images would have had false-positive goal-directed echocardiography scores, the corresponding sensitivity and specificity for right ventricular dysfunction would have been 100% (95% CI 87% to 100%) and 96% (95% CI 89% to 99%), respectively, with a positive likelihood ratio of 23.3 (95% CI 9.3 to 58.3) and negative likelihood ratio of 0 (95% CI 0 to 0.13). Likewise, if we assume that all 3 patients with poor-quality echocardiography images would have had false-negative goal-directed echocardiography scores, the

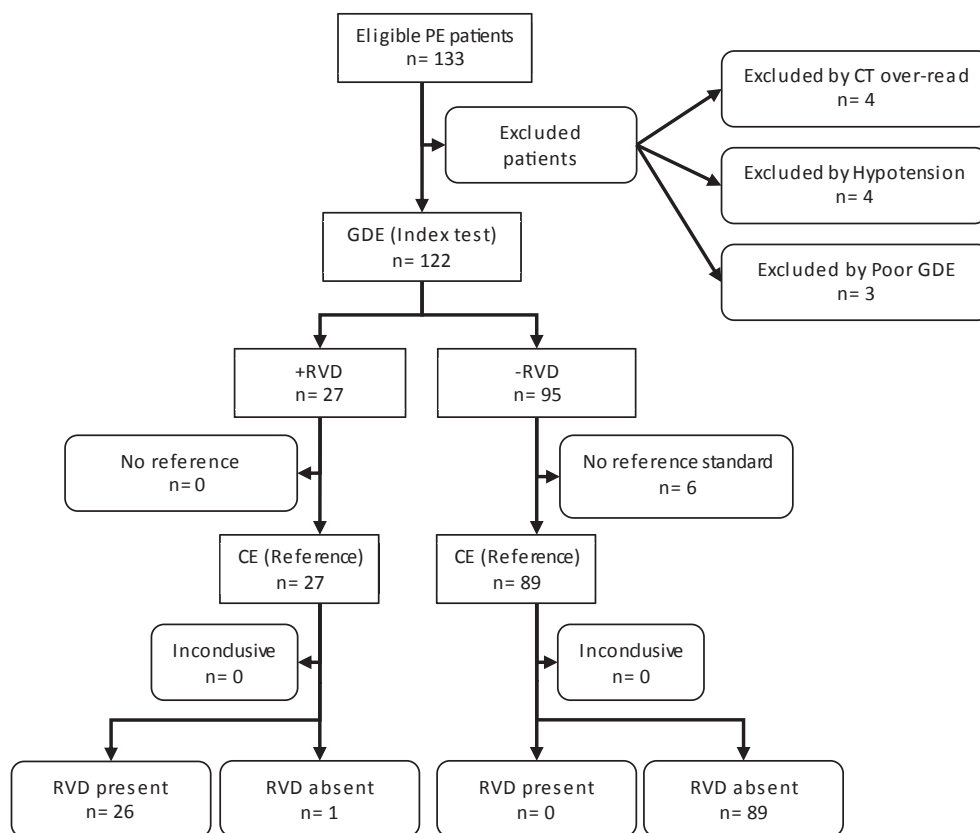


Figure 2. Study flow diagram for the goal-directed echocardiography evaluation of right ventricle dysfunction compared with comprehensive echocardiography. PE, Pulmonary embolism; CT, computed tomography; GDE, goal-directed echocardiography; RVD, right ventricular dysfunction; CE, comprehensive echocardiography.

Table 1. Clinical characteristics of enrolled pulmonary embolism patients.

Characteristics	Total (n=116)	CE With Severe RVD (n=26)	CE Without Severe RVD (n=90)	Difference (95% CI)
Age (IQR), y	59 (26)	64 (25)	58 (27)	6 (-1 to 13)
Male sex (%)	59 (51)	15 (58)	44 (49)	9 (-13 to 29)
Systolic blood pressure (IQR), mm Hg	127 (28)	125 (31)	127 (26)	-3 (-13 to 6)
Diastolic blood pressure (IQR), mm Hg	78 (23)	74 (25)	79 (21)	-2 (-10 to 5)
Pulse rate (IQR), beats/min	92 (31)	101 (23)	89 (31)	6 (-3 to 15)
Pulse oximetry on room air (%)	96 (7)	93 (7)	97 (5)	-4 (-6 to -2)
Race (%)				
White	65 (56)	15 (58)	50 (56)	2 (-20 to 22)
Black	48 (41)	10 (38)	38 (42)	-4 (-23 to 18)
Asian	2 (2)	0	2 (2)	-2 (-8 to 1.1)
American Indian	1 (1)	1 (4)	0	4 (-0.4 to 19)
Comorbid conditions (%)				
Cancer	37 (32)	8 (31)	29 (32)	-1 (-19 to 20)
End-stage renal disease	3 (3)	0	3 (3)	-3 (-9 to 10)
Congestive heart failure	7 (6)	2 (8)	5 (6)	2 (-7 to 19)
Hypertension	57 (49)	18 (69)	39 (43)	26 (4 to 44)
COPD or emphysema	18 (16)	6 (23)	12 (13)	10 (-5 to 30)
Previous PE or DVT	26 (22)	7 (27)	19 (21)	6 (-11 to 27)

COPD, Chronic obstructive pulmonary disease; DVT, deep venous thrombosis.

corresponding sensitivity and specificity for right ventricular dysfunction would have been 90% (95% CI 73% to 98%) and 99% (95% CI 94% to 100%),

respectively, with a positive likelihood ratio of 81 (95% CI 14.8 to 457.7) and negative likelihood ratio of 0.1 (95% CI 0.04 to 0.27).

Table 2. Test characteristics of goal-directed echocardiography scores, brain natriuretic peptide level, troponin level, combined cardiac biomarker scores, right ventricular:left ventricular ratio, and proximal thrombus site location by CT compared with comprehensive echocardiography for right ventricular dysfunction.*

	Comp Echo +RVD	Comp Echo -RVD	Total	Sensitivity (95% CI), %†	Specificity (95% CI), %†	+LR	-LR‡
GDE score							
1-3	26	1	27	100 (87-100)	99 (94-100)	90 (16.3-499.8)	0 (0-0.13)
0	0	89	89				
	26	90	116				
BNP							
≥90	23	28	51	88 (70-98)	68 (57-78)	2.8 (2.0-3.9)	0.17 (0.06-0.43)
<90	3	60	63				
	26	88	114				
Troponin							
≥0.07	16	6	22	62 (41-80)	93 (86-98)	9.2 (4.1-20.9)	0.41 (0.24-0.62)
<0.07	10	84	94				
	26	90	116				
Cardiac biomarker score							
1-2	25	30	55	96 (80-100)	66 (55-76)	2.8 (2.1-3.9)	0.06 (0.01-0.29)
0	1	58	59				
	26	88	114				
Most proximal thrombus location on CT							
Central/lobar	21	35	56	88 (68-97)	60 (49-70)	2.2 (1.6-2.9)	0.21 (0.07-0.53)
Segmental	3	52	55				
	24	87	111				
CT RV:LV ratio							
≥1	21	18	39	91 (72-99)	79 (69-87)	4.3 (2.8-6.7)	0.11 (0.03-0.34)
<1	2	67	69				
	23	85	108				

Comp Echo, Comprehensive echocardiography; LR, likelihood ratio; BNP, brain natriuretic peptide; RV, right ventricle; LV, left ventricle.

*Five patients had pulmonary embolism diagnosed by ventilation-perfusion scan. Two patients did not have BNP testing performed. Three patients did not have comments on CT RV: LV ratio.

†The 95% CIs for GDE did not account for clustering and the lower 95% confidence limit is likely even lower than what is reported.

‡The lower boundary of this 95% CI is inestimable as there were no false negatives, but the value tends towards zero.

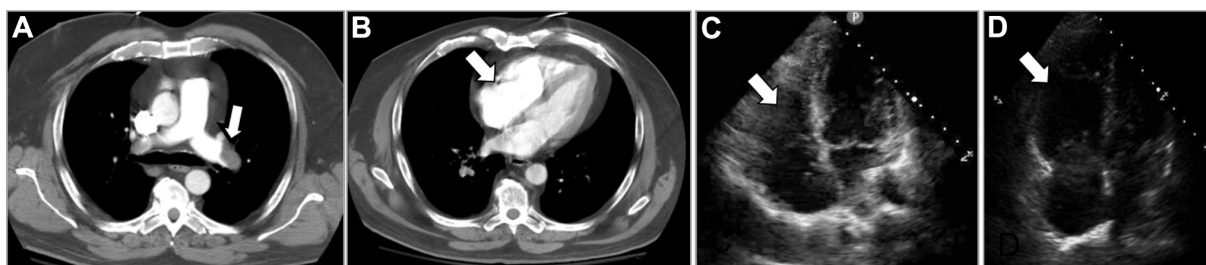


Figure 3. A, Contrast-enhanced CT of the chest showing filling defects within the pulmonary arteries. The arrow points to thrombi within the left main pulmonary artery. B, CT image of the heart and a dilated right ventricle (arrow) with a diameter greater than that of the left ventricle. C, Apical 4-chamber-view cardiac ultrasonographic view showing normal right ventricle shape and dimension (arrow). D, Cardiac ultrasonographic apical 4-chamber view of the severely dilated right ventricle (arrow).

We had 27 goal-directed echocardiography interpretations of right ventricular dysfunction: 7 of 27 had a score of 1, 5 of 27 had a score of 2, and 15 of 27 had a score of 3. Comprehensive echocardiography determined there were 26 patients with right ventricular dysfunction. The one false-positive result involved a goal-directed echocardiography score of 1 for right ventricular enlargement, but comprehensive echocardiography was read as “right ventricular upper limits of normal” with good systolic function.

There was one case of isolated poor right ventricular systolic function with poor left ventricular function but no right ventricular enlargement. The comprehensive echocardiography reading agreed; however, according to our goal-directed echocardiography criteria for pulmonary embolism-specific right ventricular dysfunction, right ventricular enlargement was a necessary condition.

Another discrepancy between goal-directed echocardiography and comprehensive echocardiography involved one patient for whom our goal-directed echocardiography score was 1, but comprehensive echocardiography reported more extensive right ventricular dysfunction with severe right ventricular enlargement, severe right ventricular systolic dysfunction, and septal deviation. In this instance, comprehensive echocardiography and goal-directed echocardiography were completed within 3 hours of each other. Both operators reported technically challenging windows, and comprehensive echocardiography used contrast to improve views.

Of patients with comprehensive echocardiography positive for right ventricular dysfunction, 25 of 26 (96%) had a cardiac biomarker score of 1 or greater and 14 of 26 (54%) had a score of 2. Among these patients, the median brain natriuretic peptide and troponin values were 321 pg/mL (interquartile range [IQR] 465) and 0.13 μ L (IQR 0.28). Among the patients with comprehensive echocardiography that was negative for right ventricular dysfunction, 89 of 90 (99%) had a biomarker score of 0, and

1 of 90 (1%) had a score of 2. Among these patients, the median (IQR) brain natriuretic peptide and troponin values were 44 pg/mL (IQR 113) and 0.01 μ L (IQR 0.02).

The test characteristics of point-of-care cardiac biomarkers (using predefined threshold values) are detailed in [Table 2](#).

Brain natriuretic peptide had a sensitivity of 88% (95% CI 70% to 98%) and specificity of 68% (95% CI 57% to 78%), whereas positive and negative likelihood ratios were 2.8 (95% CI 2.0 to 3.9) and 0.17 (95% CI 0.06 to 0.43), respectively.

Troponin had a sensitivity of 62% (95% CI 41% to 80%) and specificity of 93% (95% CI 86% to 98%). Positive and negative likelihood ratios for troponin were 9.2 (95% CI 4.1 to 20.9) and 0.41 (95% CI 0.24 to 0.62), respectively.

The combination of both cardiac biomarkers yielded a sensitivity of 96%, specificity of 66%, and positive and negative likelihood ratios of 2.8 and 0.06, respectively, when at least 1 of the 2 biomarkers was elevated (corresponding to a biomarker score of ≥ 1).

[Figure 4](#) shows the receiver operating characteristic curves for goal-directed echocardiography, brain natriuretic peptide, and troponin compared with goal-directed echocardiography. The areas under the receiver operating characteristic curves were 0.99 (95% CI 0.99 to 1) for goal-directed echocardiography, 0.83 (95% CI 0.73 to 0.94) for brain natriuretic peptide, 0.80 (95% CI 0.69 to 0.92) for troponin, and 0.88 (95% CI 0.82 to 0.94) for biomarker score.

Using a right ventricular:left ventricular ratio of 1.0 or higher for right ventricular dysfunction, the CT test characteristics were sensitivity 91% (95% CI 72% to 99%), specificity 79% (95% CI 69% to 87%); positive likelihood ratio 4.3 (95% CI 2.8 to 6.7), and negative likelihood ratio 0.11 (95% CI 0.03 to 0.34).

Interobserver agreement assessment ($n=20$) for the goal-directed echocardiography score (0 to 3) revealed a weighted (linear) Cohen’s κ of 0.69 (95% CI 0.50 to 0.88).

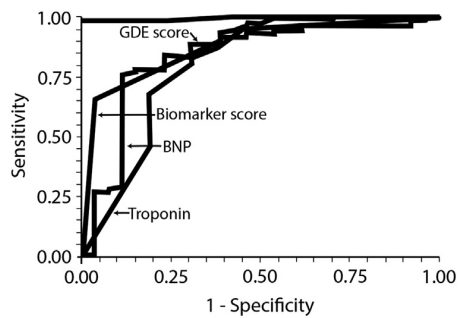


Figure 4. Receiver operating curves for goal-directed echocardiography score, biomarker score, and individual biomarkers.

In a post hoc analysis, 67% of pulmonary embolism diagnoses occurred outside of the 9 AM to 5 PM interval on weekdays (Monday through Friday). Twenty percent of our pulmonary embolism cases were diagnosed on the weekend. The average time from order placement to completion of comprehensive echocardiography was 9.4 hours.

LIMITATIONS

We performed this study at an academic center with an established emergency ultrasonographic program. Five study physicians trained in goal-directed echocardiography performed and interpreted the majority of the studies in these consecutive patients with pulmonary embolism. In the event that a study investigator was not available, goal-directed echocardiography performance was delegated to an emergency physician. This occurred 13 times during the course of the study enrollment. The availability of the equipment and expertise necessary for routine bedside goal-directed echocardiography may not be generalizable to other EDs or programs. We included a consecutive sample of patients because of around-the-clock surveillance of the ED tracking system of patients; however, it is conceivable that we missed some pulmonary embolism cases if the central paging operator was not notified by treating physicians.

Our goal-directed echocardiography criteria required severe right ventricular dilatation for right ventricular dysfunction, as widely used in previous research studies. Early right ventricular dysfunction may begin as mild to moderate dilatation and progress in severity with acute pulmonary embolism. We did not, however, assess for these intraclass distinctions. Other studies have used mild to moderate dilatation as right ventricular dysfunction in comprehensive echocardiography. It is possible that mild to moderate right ventricular dilatation would be unrecognized and be clinically significant despite initiation of anticoagulation for pulmonary embolism. If we defined right ventricular enlargement as right ventricular:left

ventricular diameter ratio greater than 0.6 (including mild and moderate right ventricular dilatation) and right ventricular systolic dysfunction as tricuspid annular planar systolic excursion less than 16 mm (including mild to moderate dysfunction) for both the index test (goal-directed echocardiography) and reference test (comprehensive echocardiography), we doubt that the accuracy of goal-directed echocardiography would be as high. We believe the qualitative right ventricular dysfunction assessment criteria we chose for goal-directed echocardiography make our diagnostic accuracy report potentially more generalizable to acute care physicians. However, 42.2% of studies were performed by the emergency fellowship director and the fellow, which may make the performance characteristics not generalizable to most emergency physicians. Additionally, 5 investigators performed 88.8% of the goal-directed echocardiography scans. Our 95% CIs for goal-directed echocardiography did not account for clustering. As such, the lower 95% confidence limit is likely lower than what is reported.

Echocardiographic findings of right ventricular dysfunction in patients with pulmonary embolism may be preexisting or not directly caused by the acute pulmonary embolism. We did not include a distinction between acute and chronic right ventricular dysfunction in our goal-directed echocardiography criteria. Chronic right ventricular dysfunction typically includes right ventricular free wall hypertrophy (thickness greater than 5 mm). We also acknowledge that a common cause of right ventricular dysfunction is severe left ventricular dysfunction, so the finding of right ventricular dysfunction must be interpreted in the context of the presence or absence of left ventricular dysfunction.

Our report does not suggest that goal-directed echocardiography negates the importance of comprehensive echocardiography, which may provide valuable information that may assist the clinician in prognostic stratification and disposition of the patient with submassive or normotensive pulmonary embolism. This includes mild to moderate right ventricular dysfunction, presence of a patent foramen ovale or mural thrombus, evidence of chronic right ventricular pressure overload, and valve dysfunction, which was not the primary focus of the goal-directed echocardiography.

There were 13 cases positive for right ventricular dysfunction or history of pulmonary embolism, or congestive heart failure or chronic obstructive pulmonary disease. None had dilated left ventricular or chronic right ventricular enlargement on reference study comprehensive echocardiography or preexisting right ventricular dysfunction by earlier comprehensive echo reports (dated before the new pulmonary embolism diagnosis).

The finding of right ventricular dysfunction does not implicate pulmonary embolism as the cause. The treating physician should consider a non-pulmonary embolism cause for right ventricular dysfunction or chronic right ventricular dysfunction in the presence of left ventricular chamber size and systolic abnormalities and right ventricular hypertrophy (suggests chronic increase of right ventricular afterload), respectively.

Use of these criteria for goal-directed echocardiography right ventricular dysfunction is meant for early right ventricular dysfunction identification and risk stratification in confirmed pulmonary embolism. Given the lower sensitivity of echocardiography for diagnosis of pulmonary embolism,^{2,29-32} use of goal-directed echocardiography in patients with suspected but not confirmed pulmonary embolism is limited to right ventricular dysfunction detection only. The presence of right ventricular dysfunction does not rule in pulmonary embolism (but can increase the likelihood of a potentially significant pulmonary embolism, if confirmed later or if the patient is unstable). Similarly, the absence of right ventricular dysfunction does not rule out pulmonary embolism.

The criteria we used for right ventricular dysfunction by CT were meant to be similar to the right ventricular:left ventricular ratio used by echocardiography. A similar right ventricular:left ventricular threshold by CT has been used and increases in right ventricular/left ventricular ratio were associated with increases in mortality risk^{33,34}; however, there are other reports that used higher ratios such as the study by Zondag et al,^{10,11} which classified right ventricular dysfunction as severe if the ratio was greater than 1.5 and moderate if it was 1.0 to 1.5. In our study, there were multiple attending radiologist observers commenting on the right ventricular:left ventricular ratio. Inter- and intraobserver agreement was not assessed. In addition, CT cardiac slices were not ECG gated and measurements may not have been taken at end diastole.

Our study evaluated serum biomarkers at a single point. We did not evaluate serial biomarker results. On a few occasions, we observed that pulmonary embolism patients with normal brain natriuretic peptide and troponin levels at enrollment had subsequently increased troponin levels despite early use of anticoagulation. In cases in which troponin levels increased, the patients were already identified as having right ventricular dysfunction by goal-directed echocardiography. Goal-directed echocardiography abnormalities occurred before biomarker elevations. One patient, who was not enrolled in the study, had normal troponin and brain natriuretic peptide levels at presentation to the ED but suddenly progressed to tachycardia and hypoxia and had significant right ventricular dysfunction

on goal-directed echocardiography. The subsequent ventilation-perfusion scan (CT not conducted because of renal impairment) was interpreted as high probability for pulmonary embolism, and both cardiac biomarker levels were markedly elevated 3 hours later.

In this study design, we investigated the accuracy of right ventricular dysfunction by goal-directed echocardiography and surrogate markers of right ventricular dysfunction and its potential as an early pulmonary embolism risk-stratification tool but did not actually investigate the clinical outcomes of the enrolled patients. In a parallel report, we will report on the prognostic performance of several variables in relation to the clinical course of the pulmonary embolism patients.

Our observers were second-year emergency medicine residents and represent an intermediate level of emergency medicine training experience in emergency echocardiography at an academic ED with a well-established emergency medicine ultrasonographic division and fellowship program. The results may not be generalizable to emergency physicians or groups without training and experience in goal-directed echocardiography. However, goal-directed echocardiography has been a part of the emergency medicine residency curriculum for several years.¹⁴ The core and advanced applications for echocardiography include detection of right ventricular enlargement and chamber size evaluation and comparison. They do not include evaluation of right ventricular systolic function. There are several practical challenges with comprehensive echocardiography. We calculated a weighted Cohen's κ of 0.69 for the goal-directed echocardiography score, representing substantial interobserver agreement.³⁵ As testimony to the complexity of right ventricular assessment, the observer agreement reports on right ventricular interpretation have been varied. Reports included κ of 0.6 between cardiologists using qualitative and quantitative comprehensive echocardiography, κ of 0.9 for cardiologists making qualitative right ventricular assessments, and κ of 0.44 in a retrospective study of emergency physician-performed right ventricular dilatation assessments and comprehensive echocardiography.^{4,36,37}

Our interobserver test focused only on image interpretation. Image acquisition is the other important component of goal-directed echocardiography and requires practice and a better understanding of the limitations of each cardiac window for features of right ventricular dysfunction to avoid overestimations and underestimations of right ventricular size.

DISCUSSION

The importance of evaluating for right ventricular dysfunction in acute pulmonary embolism has been well

described in the literature; however, there is no consensus on the optimal combination of right ventricular dysfunction assessment tools. The American Heart Association states that findings of right ventricular dysfunction by echocardiography identify patients at increased risk for adverse outcomes.⁵ The European Society of Echocardiography guidelines have emphasized use of cardiac biomarkers and echocardiography in differentiating patients with normotensive pulmonary embolism into intermediate- and low-risk categories for short-term (in-hospital) adverse outcomes.³² In addition, the American Society of Echocardiography and ACEP issued a consensus statement supporting the use of goal-directed echocardiography as a tool to facilitate rapid diagnosis and to prompt emergency treatments and decisionmaking by the emergency physician. One of the main clinical indications for goal-directed echocardiography is the detection of right ventricular enlargement.

This prospective study reports the diagnostic accuracy of emergency physician-performed goal-directed echocardiography to detect right ventricular dysfunction among stable ED patients receiving a diagnosis of pulmonary embolism. We also compared goal-directed echocardiography with a panel of predefined tests and surrogate markers for right ventricular dysfunction, using comprehensive echocardiography as the criterion standard. Abnormalities on comprehensive echocardiography, increased serum cardiac biomarker levels, and an increased right ventricular:left ventricular ratio on CT have all been shown to correlate with adverse outcomes in acute pulmonary embolism. Rapidly obtaining this information with point-of-care testing in the ED may allow a more expedient evaluation of short- and long-term risk and therefore lead to a more rapid risk stratification and treatment plan. Use of different right ventricular dysfunction assessment tools is neither multiplicative nor duplicative because each marker evaluates right heart strain differently. As a combined panel, they complement one another and may reinforce diagnostic certainty.

Unlike previous reports that included patients with hypotensive pulmonary embolism, our study focused on normotensive patients with acute pulmonary embolism. The clinical characteristics of our patients are shown in [Table 1](#). Patients with and without right ventricular dysfunction were similar with respect to blood pressure and oxygen saturation. The right ventricular dysfunction group, however, was older. Although the right ventricular dysfunction group had slightly higher pulse rates than the non-right ventricular dysfunction group, on average, neither group demonstrated tachycardia. We believe that this further emphasizes the importance of additional risk-stratification tools in the assessment of normotensive acute

pulmonary embolism patients because identification by abnormal vital signs appears suboptimal.

Comprehensive echocardiography requires the cardiac sonographer to perform multiple elaborate measurements and requires a cardiologist for interpretation. However, it is not always immediately available. In contrast, goal-directed echocardiography can be immediately available for both performance and interpretation by the treating physician. We used qualitative 2-dimensional assessments of right ventricular size, its systolic function, and septal contour ([Figure 1](#)). Goal-directed echocardiography was not used to assess for septal defects, quantitative measurements, or include Doppler or M-mode technology and did not include inferior vena cava assessments.

One third of the normotensive pulmonary embolism cases were diagnosed outside of traditional office hours. The high diagnostic accuracy of goal-directed echocardiography for right ventricular dysfunction provides evidence that it can help expedite risk stratification of pulmonary embolism.

On a few occasions, goal-directed echocardiography discovered additional findings of pulmonary embolism. There were 2 cases in which thrombi were observed swirling within the dilated and dysfunctional right ventricle. In these cases, there was increased urgency and consideration by the critical care consulting team for thrombolysis. There was another pulmonary embolism patient excluded who had severe right ventricular dysfunction by goal-directed echocardiography because comprehensive echocardiography was not performed before advanced pulmonary embolism therapy. Systemic thrombolysis was administered according to goal-directed echocardiography, elevated cardiac biomarker levels, and a computed tomography angiography right ventricular:left ventricular ratio of 1.5. Seven hours after thrombolysis, comprehensive echocardiography showed normal right ventricular size and systolic function. McConnell's sign was appreciated in 3 cases of right ventricular dysfunction.

Previous studies involving emergency physician assessment of right ventricular dysfunction with echocardiography were retrospective, and right ventricular dysfunction criteria differed from that on comprehensive echocardiography. Of the prospective studies involving comprehensive echocardiography, some have used right ventricular hypokinesis alone, whereas others used different measurements, criteria, and permutations for right ventricular dilatation, systolic dysfunction, and Doppler-derived right ventricular systolic pressure.^{18,38-40}

Our goal-directed echocardiography scoring system for right ventricular dysfunction was based on the determination of the presence or absence of severe right

ventricular enlargement. This was specifically tailored to the unique pathophysiology of acute pulmonary embolism in which right ventricular enlargement precedes right ventricular systolic dysfunction and septal deviation. For this reason, right ventricular enlargement was a required condition to report on right ventricular systolic dysfunction or septal deviation. To our knowledge, this is one of the first prospective studies of emergency physician diagnostic accuracy with qualitative tricuspid annular planar systolic excursion estimations of right ventricular systolic function. Like that in previous reports, the contemporaneous diagnostic accuracy of left ventricular systolic function by emergency physicians in this study was excellent.⁴¹⁻⁴³

Troponin elevations are indicative of myocardial ischemia, with decreased right ventricular contractility in the setting of acute pulmonary embolism. In our report, troponin-level elevations were fairly specific but lacked sensitivity for right ventricular enlargement. However, an increase in troponin level was more specifically predictive of right ventricular systolic dysfunction. This is consistent with previous reports of elevated troponin level being predictive of right ventricular systolic dysfunction.^{18,44} As recommended by the American Heart Association, we used a brain natriuretic peptide level threshold of 90 pg/mL or higher for the presence of right ventricular dysfunction. Previous studies have used different brain natriuretic peptide tests and different cutoff values and have reported on the prognostic accuracy of adverse events and mortality, not the diagnostic accuracy compared with that of comprehensive echocardiography.¹⁸ Elevated troponin and brain natriuretic peptide levels are associated with 5- to 7-fold increases in mortality of pulmonary embolism patients compared with those with normal biomarker levels. In a 2009 meta-analysis by Lega et al,⁴⁵ the combination of brain natriuretic peptide and troponin level elevations increased the risk of death in initially normotensive patients with pulmonary embolism, whereas normal values for both biomarkers were associated with significantly lower rates of deaths and adverse events.

Overall, goal-directed echocardiography performed better than level of both brain natriuretic peptide and troponin for early right ventricular dysfunction detection, as shown by the receiver operating curve analysis (Figure 4).

CT findings of filling defects within the pulmonary arteries are diagnostic of pulmonary embolism. Thrombus location and clot burden are easily assessable. Markers of right ventricular dysfunction include septal displacement, reflux of contrast into the inferior vena cava, and increased right ventricular:left ventricular diameter ratio. The right ventricular:left ventricular ratio is considered to have the strongest predictive value for adverse events in pulmonary

embolism patients.⁴⁶ Our study used a threshold of right ventricular:left ventricular ratio greater than or equal to 1.0 to assess right ventricular dysfunction.

The 91% sensitivity of CT for right ventricular dysfunction shows the importance of radiologists' inclusion of the right ventricular:left ventricular ratio measurement on CT reports that confirm the diagnosis of pulmonary embolism.

There has been conflicting evidence about the association of clot location or size and right ventricular dysfunction on comprehensive echocardiography. Berghaus et al⁴⁷ found that a central location of thromboembolism was an independent predictor of right ventricular dysfunction on comprehensive echocardiography. However, Kline et al⁴ found no association between percentage of pulmonary arterial occlusion and blood pressure, pulse rate, oxygenation status, and cardiac biomarkers (troponin I and brain natriuretic peptide). Pruszczyk et al⁴⁸ showed similar echocardiographic parameters between patients with and without saddle pulmonary emboli. We found that central or lobar clot location was not predictive of right ventricular dysfunction, with 21 of 56 patients (38%) who had central or lobar clots also having right ventricular dysfunction on comprehensive echocardiography. Central or lobar clot location had a sensitivity of 88%, specificity of 60%, and a positive likelihood ratio of 2.2 for right ventricular dysfunction on comprehensive echocardiography. This suggests that clot size and its most proximal location are not as important parameters in determining potential for deterioration in an initially stable pulmonary embolism patient.

Cardiac brain natriuretic peptide level elevations are not specific for cardiac chamber enlargement and may be elevated because of atrial, right ventricular, or left ventricular enlargement. Our cohort of patients with right ventricular dysfunction by goal-directed echocardiography had higher mean cardiac biomarker levels than those without right ventricular dysfunction. Some authors have suggested that echocardiography can assist in risk stratification of stable pulmonary embolism patients with elevated cardiac biomarker levels.³ The addition of goal-directed echocardiography offers direct observation of each cardiac chamber and allows cardiac chamber evaluation, quantification, and comparison. As an example, one of our subjects had a brain natriuretic peptide level greater than 1,000 pg/mL and normal troponin level; however, goal-directed echocardiography showed significant left ventricular hypertrophy, decreased left ventricular chamber size and mildly increased right ventricular dilatation, and significant biatrial enlargement. CT suggested that the right ventricular:left ventricular ratio was not increased. In this case, goal-directed echocardiography was able to clarify that the elevated brain natriuretic peptide level was due to atrial

enlargement, not pulmonary embolism–related right ventricular dysfunction.

The meta-analysis by Lega et al⁴⁵ showed that pulmonary embolism patients with elevated levels of both brain natriuretic peptide and troponin had an increased risk of adverse outcomes. It is likely that dual elevations of brain natriuretic peptide and troponin level may represent an advanced stage of right ventricular dysfunction caused by pulmonary embolism. In other studies, the combination of right ventricular dysfunction by echocardiography and elevated troponin level was associated with worse clinical outcome. In addition, the severity of right ventricular dysfunction was accentuated in patients with troponin level elevations.^{18,22,44,49}

In summary, in our patient and provider population, emergency physician–performed goal-directed echocardiography had excellent sensitivity and specificity for identification of severe right ventricular dysfunction in ED patients who received a diagnosis of acute pulmonary embolism. Cardiac brain natriuretic peptide level was reasonably sensitive but less specific, and troponin level was quite specific but insensitive. Area under the receiver operating characteristic curve analysis likewise favored goal-directed echocardiography. Future research objectives may include determining the relationship between goal-directed echocardiography and patient-centered clinical outcomes and assessing the reproducibility of severe right ventricular dysfunction interpretation of goal-directed echocardiography among point-of-care physicians.

Supervising editor: William R. Mower, MD, PhD

Author affiliations: From the Department of Emergency Medicine, Carolinas Medical Center, Charlotte, NC.

Author contributions: AJW and DT conceived the study and designed the trial. AJW supervised the conduct of the trial and data collection. AJW, GT, DT, AKJ, and JC-B enrolled patients. MR provided statistical advice on study design and analyzed the data. AJW and GT managed the data, including quality control, and drafted the article. All authors contributed substantially to article revision. AJW takes responsibility for the paper as a whole.

Funding and support: By *Annals* policy, all authors are required to disclose any and all commercial, financial, and other relationships in any way related to the subject of this article as per ICMJE conflict of interest guidelines (see www.icmje.org). The authors have stated that no such relationships exist.

Publication dates: Received for publication August 6, 2015. Revisions received September 23, 2015; December 1, 2015, and December 29, 2015. Accepted for publication January 21, 2016. Available online March 11, 2016.

Presented at the Society of Academic Emergency Medicine annual meeting, May 2015, San Diego, CA.

REFERENCES

- Fengler BT, Brady WJ. Fibrinolytic therapy in pulmonary embolism: an evidence-based treatment algorithm. *Am J Emerg Med.* 2009;27:84-95.
- Fesmire FM, Brown MD, Espinosa JA, et al. Critical issues in the evaluation and management of adult patients presenting to the emergency department with suspected pulmonary embolism. *Ann Emerg Med.* 2011;57:628-652.e75.
- Kucher N, Goldhaber SZ. Cardiac biomarkers for risk stratification of patients with acute pulmonary embolism. *Circulation.* 2003;108:2191-2194.
- Kline JA, Steuerwald MT, Marchick MR, et al. Prospective evaluation of right ventricular function and functional status 6 months after acute submassive pulmonary embolism: frequency of persistent or subsequent elevation in estimated pulmonary artery pressure. *Chest.* 2009;136:1202-1210.
- Jaff MR, McMurtry MS, Archer SL, et al. Management of massive and submassive pulmonary embolism, iliofemoral deep vein thrombosis, and chronic thromboembolic pulmonary hypertension: a scientific statement from the American Heart Association. *Circulation.* 2011;123:1788-1830.
- Sharifi M, Bay C, Skrocki L, et al. Moderate pulmonary embolism treated with thrombolysis (from the “MOPETT” trial). *Am J Cardiol.* 2013;111:273-277.
- Kasper W, Konstantinides S, Geibel A, et al. Prognostic significance of right ventricular afterload stress detected by echocardiography in patients with clinically suspected pulmonary embolism. *Heart.* 1997;77:346-349.
- Aujesky D, Obrosky DS, Stone RA, et al. Derivation and validation of a prognostic model for pulmonary embolism. *Am J Respir Crit Care Med.* 2005;172:1041-1046.
- Aujesky D, Roy PM, Verschuren F, et al. Outpatient versus inpatient treatment for patients with acute pulmonary embolism: an international, open-label, randomised, non-inferiority trial. *Lancet.* 2011;378:41-48.
- Zondag W, den Exter PL, Crobach MJ, et al. Comparison of two methods for selection of out of hospital treatment in patients with acute pulmonary embolism. *Thromb Haemost.* 2013;109:47-52.
- Zondag W, Hiddinga BI, Crobach MJ, et al. Hestia criteria can discriminate high- from low-risk patients with pulmonary embolism. *Eur Respir J.* 2013;41:588-592.
- American College of Emergency Physicians. Emergency ultrasound guidelines 2008. Available at: <http://www.acep.org/workarea/DownloadAsset.aspx?id=32878>. Accessed August 15, 2015.
- Labovitz AJ, Noble VE, Bierig M, et al. Focused cardiac ultrasound in the emergent setting: a consensus statement of the American Society of Echocardiography and American College of Emergency Physicians. *J Am Soc Echocardiogr.* 2010;23:1225-1230.
- Lewis RE, Pearl M, Nomura JT, et al. CORD-AEUS: consensus document for the Emergency Ultrasound Milestone Project. *Acad Emerg Med.* 2013;20:740-745.
- Park JR, Chang SA, Jang SY, et al. Evaluation of right ventricular dysfunction and prediction of clinical outcomes in acute pulmonary embolism by chest computed tomography: comparisons with echocardiography. *Int J Cardiovasc Imaging.* 2012;28:979-987.
- Cho JH, Kutti Sridharan G, Kim SH, et al. Right ventricular dysfunction as an echocardiographic prognostic factor in hemodynamically stable patients with acute pulmonary embolism: a meta-analysis. *BMC Cardiovasc Disord.* 2014;14:64.
- Coutance G, Cauderlier E, Ehtisham J, et al. The prognostic value of markers of right ventricular dysfunction in pulmonary embolism: a meta-analysis. *Crit Care.* 2011;15:R103.
- Sanchez O, Trinquart L, Colombet I, et al. Prognostic value of right ventricular dysfunction in patients with haemodynamically stable

- pulmonary embolism: a systematic review. *Eur Heart J*. 2008;29:1569-1577.
19. Horton KD, Meece RW, Hill JC. Assessment of the right ventricle by echocardiography: a primer for cardiac sonographers. *J Am Soc Echocardiogr*. 2009;22:776-792; quiz 861-862.
 20. Lindqvist P, Calcutteea A, Henein M. Echocardiography in the assessment of right heart function. *Eur J Echocardiogr*. 2008;9:225-234.
 21. Bruhl SR, Chahal M, Khouri SJ. A novel approach to standard techniques in the assessment and quantification of the interventricular systolic relationship. *Cardiovasc Ultrasound*. 2011;9:42.
 22. Pruszczyk P, Goliszek S, Lichodziejewska B, et al. Prognostic value of echocardiography in normotensive patients with acute pulmonary embolism. *JACC Cardiovasc Imaging*. 2014;7:553-560.
 23. Stamm JA, Long JL, Kirchner HL, et al. Risk stratification in acute pulmonary embolism: frequency and impact on treatment decisions and outcomes. *South Med J*. 2014;107:72-78.
 24. Wood KE. Major pulmonary embolism: review of a pathophysiologic approach to the golden hour of hemodynamically significant pulmonary embolism. *Chest*. 2002;121:877-905.
 25. Buderer NM. Statistical methodology: I. Incorporating the prevalence of disease into the sample size calculation for sensitivity and specificity. *Acad Emerg Med*. 1996;3:895-900.
 26. Harris PA, Taylor R, Thielke R, et al. Research electronic data capture (REDCap)—a metadata-driven methodology and workflow process for providing translational research informatics support. *J Biomed Inform*. 2009;42:377-381.
 27. Williams RL. A note on robust variance estimation for cluster-correlated data. *Biometrics*. 2000;56:645-646.
 28. DeLong ER, DeLong DM, Clarke-Pearson DL. Comparing the areas under two or more correlated receiver operating characteristic curves: a nonparametric approach. *Biometrics*. 1988;44:837-845.
 29. Dresden S, Mitchell P, Rahimi L, et al. Right ventricular dilatation on bedside echocardiography performed by emergency physicians aids in the diagnosis of pulmonary embolism. *Ann Emerg Med*. 2014;63:16-24.
 30. Jackson RE, Rudoni RR, Hauser AM, et al. Prospective evaluation of two-dimensional transthoracic echocardiography in emergency department patients with suspected pulmonary embolism. *Acad Emerg Med*. 2000;7:994-998.
 31. Fesmire FM, Brown MD, Espinosa JA, et al. Critical issues in the evaluation and management of adult patients presenting with suspected pulmonary embolism. *Ann Emerg Med*. 2011;57:628-652.e75.
 32. Konstantinides SV. 2014 ESC guidelines on the diagnosis and management of acute pulmonary embolism. *Eur Heart J*. 2014;35:3145-3146.
 33. van der Meer RW, Pattynama PM, van Strijen MJ, et al. Right ventricular dysfunction and pulmonary obstruction index at helical CT: prediction of clinical outcome during 3-month follow-up in patients with acute pulmonary embolism. *Radiology*. 2005;235:798-803.
 34. Ghuyen A, Ghaye B, Willems V, et al. Computed tomographic pulmonary angiography and prognostic significance in patients with acute pulmonary embolism. *Thorax*. 2005;60:956-961.
 35. Landis JR, Koch GG. The measurement of observer agreement for categorical data. *Biometrics*. 1977;33:159-174.
 36. Kopečna D, Briongos S, Castillo H, et al. Interobserver reliability of echocardiography for prognostication of normotensive patients with pulmonary embolism. *Cardiovasc Ultrasound*. 2014;12:29.
 37. Taylor RA, Moore CL. Accuracy of emergency physician-performed limited echocardiography for right ventricular strain. *Am J Emerg Med*. 2014;32:371-374.
 38. Pieralli F, Olivotto I, Vanni S, et al. Usefulness of bedside testing for brain natriuretic peptide to identify right ventricular dysfunction and outcome in normotensive patients with acute pulmonary embolism. *Am J Cardiol*. 2006;97:1386-1390.
 39. Pollack CV, Schreiber D, Goldhaber SZ, et al. Clinical characteristics, management, and outcomes of patients diagnosed with acute pulmonary embolism in the emergency department: initial report of EMPEROR (Multicenter Emergency Medicine Pulmonary Embolism in the Real World Registry). *J Am Coll Cardiol*. 2011;57:700-706.
 40. Vieillard-Baron A, Page B, Augarde R, et al. Acute cor pulmonale in massive pulmonary embolism: incidence, echocardiographic pattern, clinical implications and recovery rate. *Intensive Care Med*. 2001;27:1481-1486.
 41. Moore CL, Rose GA, Tayal VS, et al. Determination of left ventricular function by emergency physician echocardiography of hypotensive patients. *Acad Emerg Med*. 2002;9:186-193.
 42. Randazzo MR, Snoey ER, Levitt MA, et al. Accuracy of emergency physician assessment of left ventricular ejection fraction and central venous pressure using echocardiography. *Acad Emerg Med*. 2003;10:973-977.
 43. Weekes AJ, Tassone HM, Babcock A, et al. Comparison of serial qualitative and quantitative assessments of caval index and left ventricular systolic function during early fluid resuscitation of hypotensive emergency department patients. *Acad Emerg Med*. 2011;18:912-921.
 44. Penalzoza A, Roy PM, Kline J. Risk stratification and treatment strategy of pulmonary embolism. *Curr Opin Crit Care*. 2012;18:318-325.
 45. Lega JC, Lacasse Y, Lakhal L, et al. Natriuretic peptides and troponins in pulmonary embolism: a meta-analysis. *Thorax*. 2009;64:869-875.
 46. Meinel FG, Nance JW Jr, Schoepf UJ, et al. Predictive value of computed tomography in acute pulmonary embolism: systematic review and meta-analysis. *Am J Med*. 2015;128:747-759.
 47. Berghaus TM, Haeckel T, Behr W, et al. Central thromboembolism is a possible predictor of right heart dysfunction in normotensive patients with acute pulmonary embolism. *Thromb Res*. 2010;126:e201-e205.
 48. Pruszczyk P, Pacho R, Ciurzynski M, et al. Short term clinical outcome of acute saddle pulmonary embolism. *Heart*. 2003;89:335-336.
 49. Pruszczyk P, Bochowicz A, Torbicki A, et al. Cardiac troponin T monitoring identifies high-risk group of normotensive patients with acute pulmonary embolism. *Chest*. 2003;123:1947-1952.

Did you know?

Continuing Medical Education for *Annals* articles is available at <http://www.acep.org/ACEPeCME/>.